

د.رغد کامل

5th stage

EXAMINATION OF A GYNECOLOGICAL PATIENT

The clinical examination should be thorough and meticulous. These include in-depth history taking and examinations—general, abdominal and internal. It should be emphasized that a meticulous history taking alone can give a positive diagnosis in majority of cases without any physical examination.

The examination should, in fact, proceed with the provisional diagnosis in mind.

Name Age

.....

Address

Marital status Parity

Social status

Chief complaint

Menstrual History: Enquiry should be made about:

- Age of onset of the first period (menarche).
- Regularity of the cycle
- Duration of period
- Length of the cycle
- Amount of bleeding—Excess is indicated by the passage of clots or number of pads used
- First day of the last menstrual period (LMP).

The menstrual history can be reproduced as 13/4/28, representing that the onset of period was at the age of 13, bleeding lasts for 4 days and occurs every 28 days.

Obstetric History: If the patient had been previously pregnant, details are to be enquired as per tabulation below. Many a times, the complaints may be related to the pregnancy complications or lactation.

No. date	Year and events	Pregnancy events	Labor delivery	Method of delivery	Puerperium	Baby weight and sex. Birth asphyxia. Duration of breastfeeding, contraception

The obstetric history is to be summed up as—

No. of living children

.....Boys.....Girls.....

Health status of the baby

.....

Immunization Last child birth

.....

Past Medical History

Relevant medical disorders—systemic, metabolic or endocrinal (diabetes, hypertension, hepatitis) should be enquired.

Past Surgical History

This includes general, obstetrical or gynecological surgery. The nature of the operation, anesthetic procedures, bleeding or clotting complication if any, postoperative convalescence are to be enquired. Any histopathological report or relevant investigation related to the previous surgery is most often helpful.

Family History

It is of occasional value. Malignancy of the breast, colon, ovary or endometrium is often related.

Tubercular affection of any family member can give a clue in diagnosis of pelvic tuberculosis.

Personal History

Occupation, marital status—married, widow, divorced or separated should be enquired. If married—details of sexual history should be taken, especially in case of infertility. Sexual history includes any sexual dysfunction, or dyspareunia. Contraceptive practice, if any should be enquired—especially relevant in pill users or cases having IUCD, as these methods often produce some adverse symptoms. History of taking drugs for a long time or allergy to certain drugs is to be noted.

EXAMINATION

The examination includes:

General and systemic examination

Gynecological examination

Breast examination

Abdominal examination

Pelvic examination.

GENERAL AND SYSTEMIC EXAMINATION

The general and systemic examination should be thorough and meticulous.

Built—Too obese or too thin—May be the result of endocrinopathy and related to menstrual abnormalities

Nutrition—Average/Poor

Stature—Including development of secondary sex characters

Pallor

Jaundice

Edema of legs

Teeth, gums and tonsils—For any septic foci

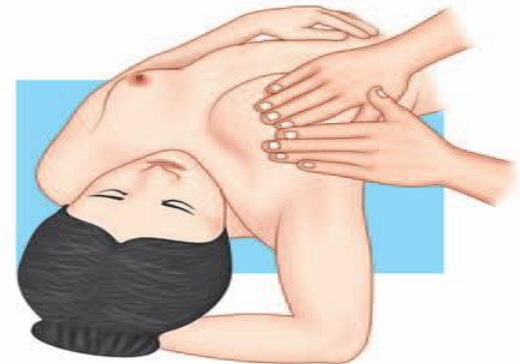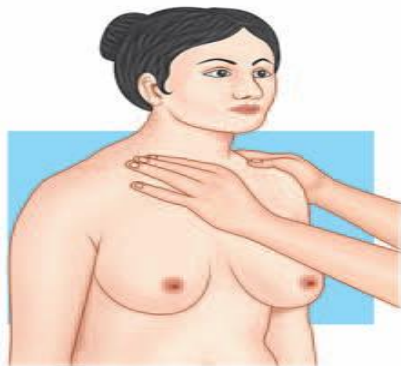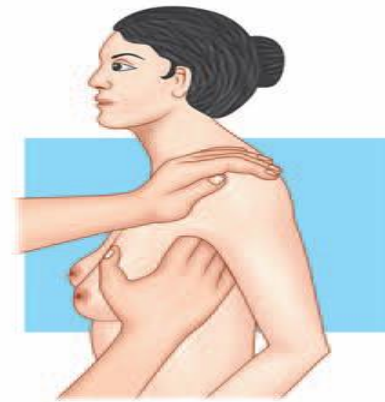
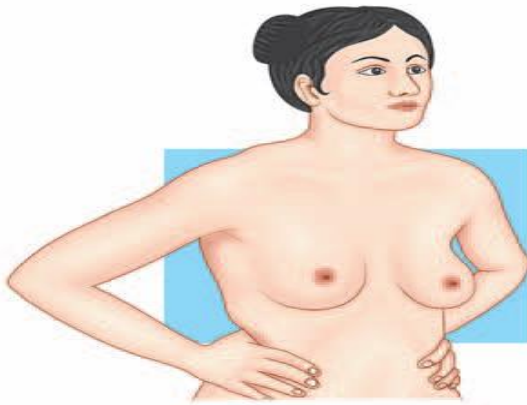
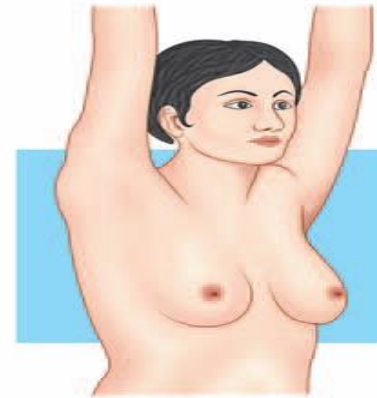
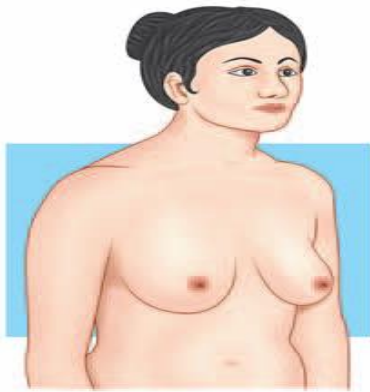
Neck—Palpation of thyroid gland and lymph nodes, especially the left supraclavicular glands

Cardiovascular and respiratory systems—Any abnormality may modify the surgical procedure, if it deems necessary

Pulse Blood pressure.

Breast Examination (Fig. 9.1)

This should be a routine especially in women above the age of 30 to detect any breast pathology, the important being carcinoma. In India, **breast carcinoma is the second most common malignancy in female, next to carcinoma cervix.**



Abdominal examination

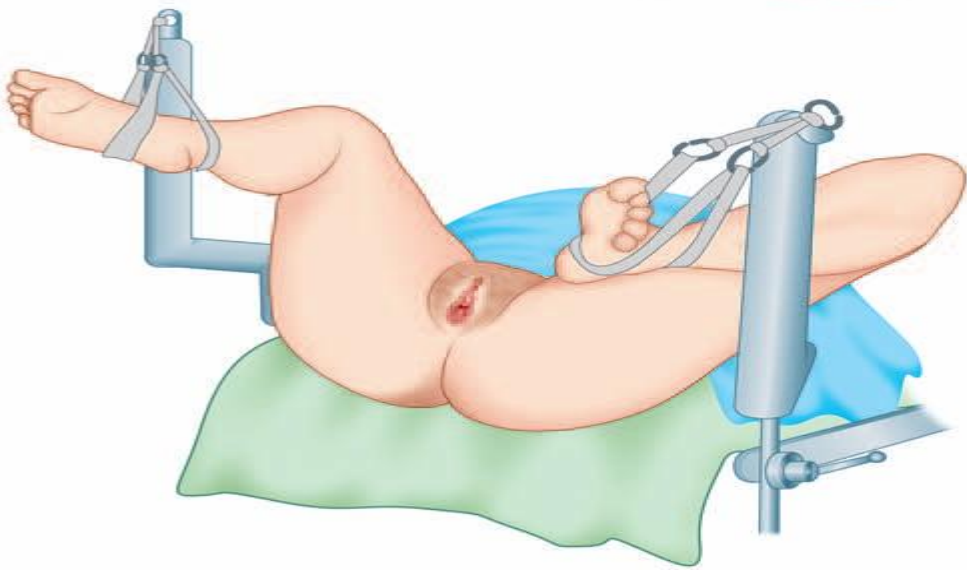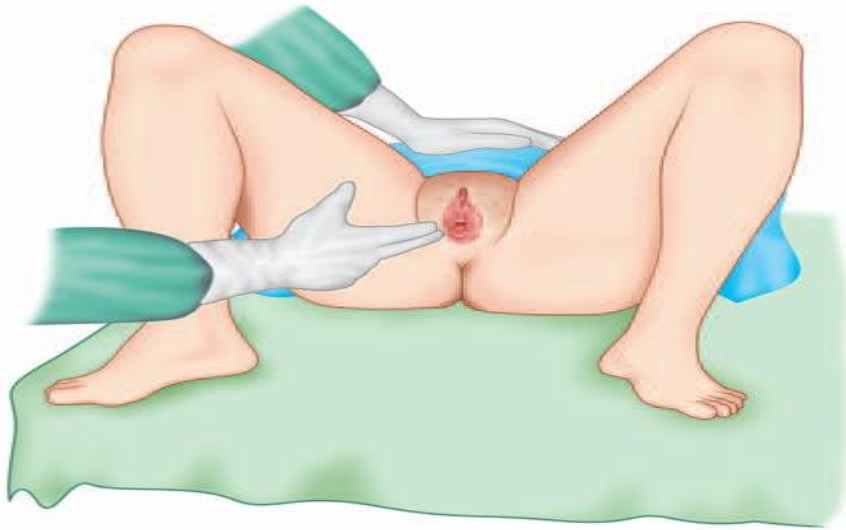
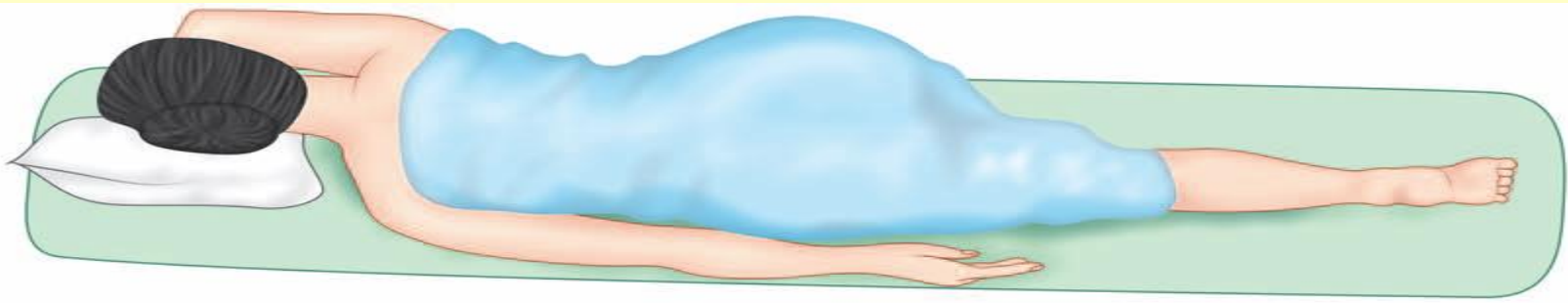Prerequisites

- Bladder should be empty.** The only exception to the procedure is the presence of history suggestive of stress incontinence. If history is suggestive of chronic retention of urine, catheterization should be done taking aseptic precautions, using sterile simple rubber catheter
- The patient is to lie flat on the table** with the thighs slightly flexed and abducted to make the abdominal muscles relaxed (see Fig. 9.3B)
- The physician usually prefers to stand on the right side**
- Presence of a chaperone** (a female) for the support of the patient and the physician.

Actual steps:

Palpation Inspection

Auscultation Percussion



PELVIC EXAMINATION

Pelvic examination includes:

Inspection of the external genitalia

Vaginal examination

- Inspection of the cervix and vaginal walls
- Palpation of the vagina and vaginal cervix by digital examination
- Bimanual examination of the pelvic organs

Rectal examination

Rectovaginal examination.

PREREQUISITES

- The patient's bladder must be empty—the exception being a case of stress incontinence
 - A female attendant (nurse or relative of the patient) should be present by the side
 - To examine a minor or unmarried, a consent from the parent or guardian is required
 - Lower bowel (rectum and pelvic colon) should preferably be empty
 - A light source should be available
- Sterile gloves, sterile lubricant (preferably colorless without any antiseptics), speculum, sponge holding forceps and swabs are required

POSITION OF THE PATIENT

Dorsal position with the knees flexed and thighs abducted.

Lateral or Sims' position seems ideal for inspecting any lesion in anterior vaginal wall

Lithotomy position (patient lying supine with her legs on stirrups) is ideal for examination under anesthesia.

INSPECTION OF THE VULVA (FIG. 9.4)

- To note any anatomical abnormality starting from the pubic hair, clitoris, labia and perineum
- To note any palpable pathology over the areas
- To note the character of the visible vaginal discharge, if any
- To separate the labia using fingers of the left hand to note external urethral meatus, visible openings of the Bartholin's ducts (normally not visible unless inflamed) and character of the hymen.
- To ask the patient to strain to elicit:
 - Stress incontinence—urine comes out through urethral meatus (see p. 399).
 - Genital prolapse and the structures involved— anterior vaginal wall, uterus alone or posterior vaginal wall or all the three (see p. 204).
- Lastly, to look for hemorrhoids, anal fissure, anal fistula or perineal tear.

VAGINAL EXAMINATION

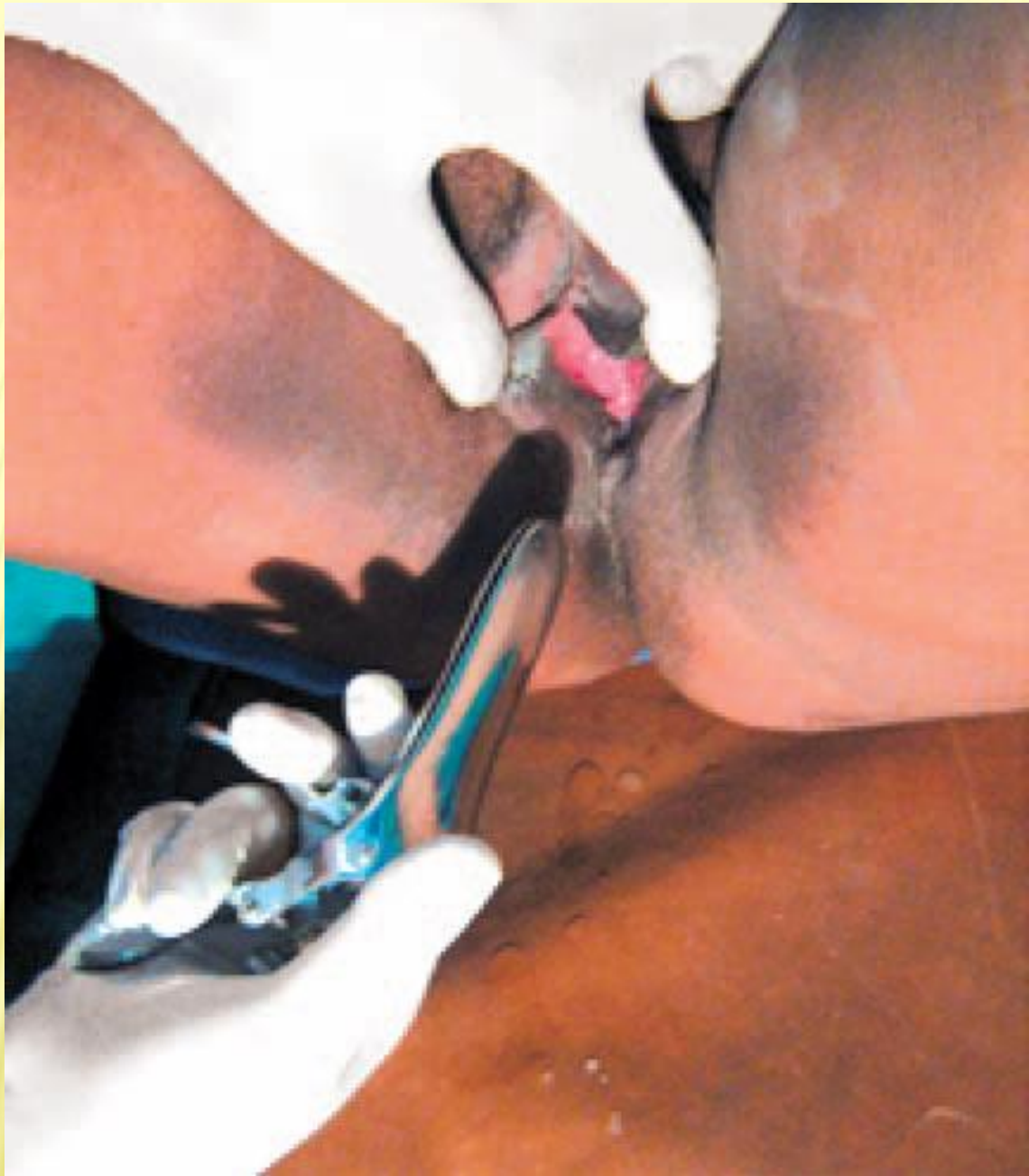Inspection of the vagina and cervix

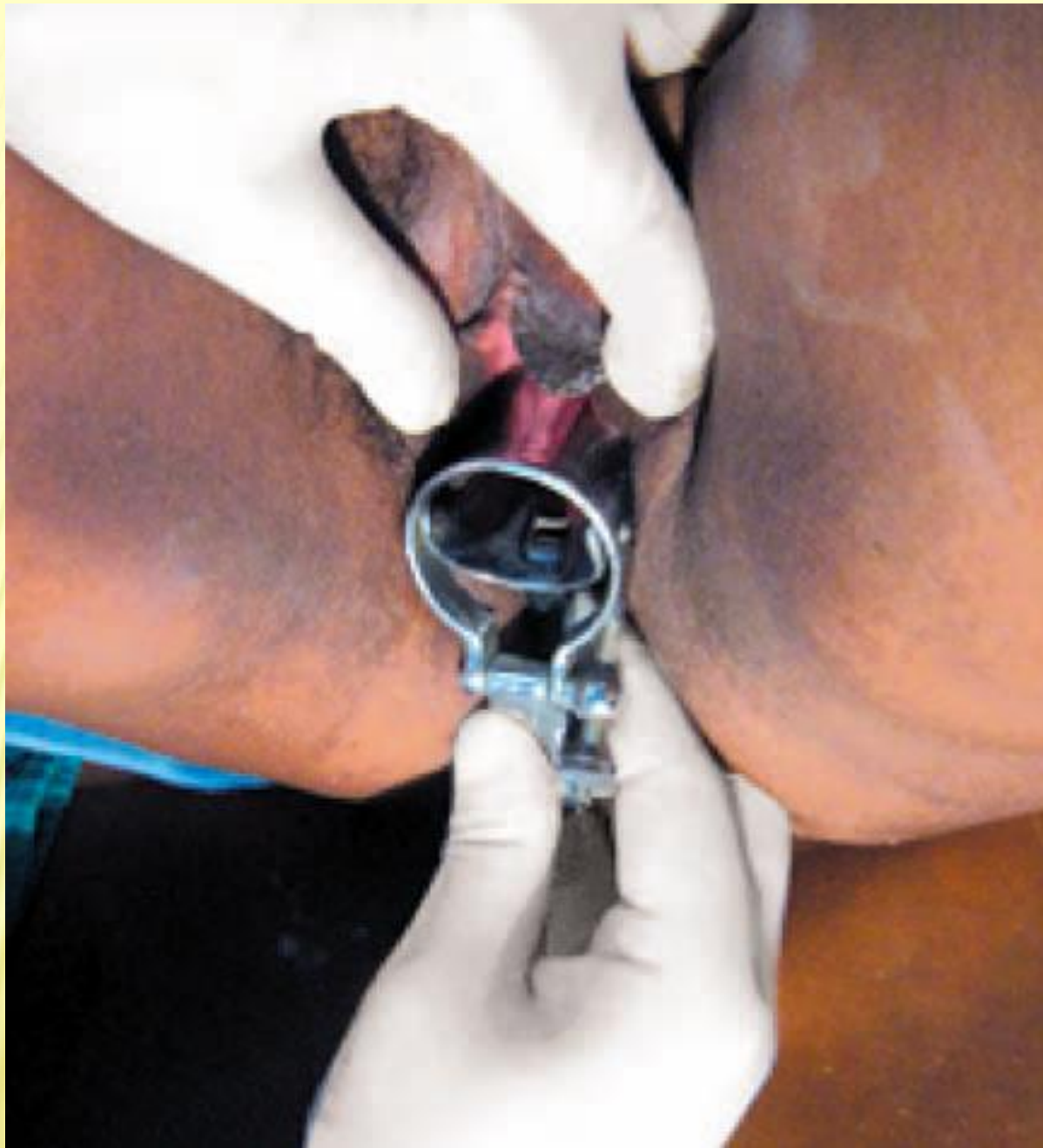Which one is to be done first—inspection or palpation?

Speculum examination should preferably be done prior to bimanual examination. **The advantages are:**

- Cervical scrape cytology and endocervical sampling can be taken as ‘screening’ in the same sitting
- Cervical or vaginal discharge can be taken for bacteriological examination
- The cervical lesion may bleed during bimanual examination, which makes the lesion difficult to visualize.

Two types of speculum are commonly used—Sims’ or Cusco’s bivalve. **While in dorsal position, Cusco is widely used**






Digital examination

Digital examination is done using a gloved index finger lubricated with sterile lubricant. In virgins with intact hymen, this examination is withheld but can be employed under anesthesia.

Palpation of any labial swelling

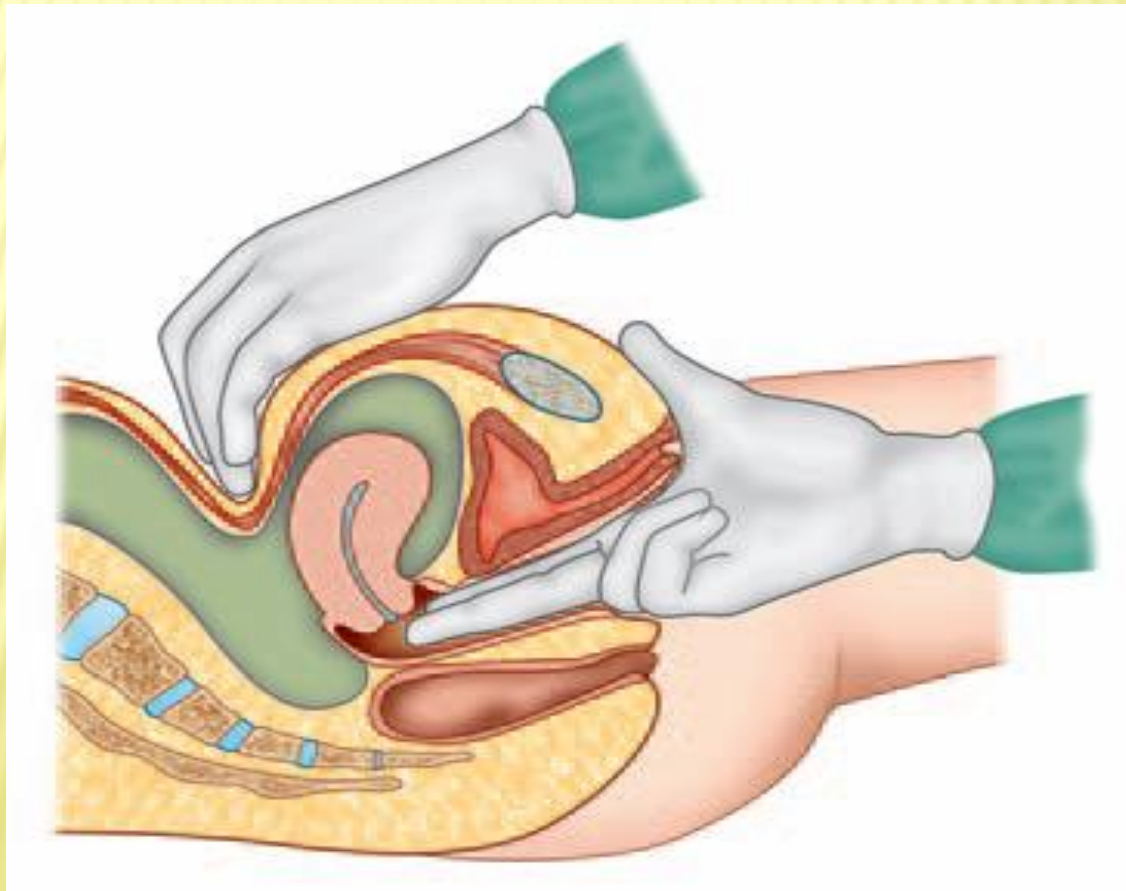
Palpation of the vaginal walls is to be done from below upwards to detect any abnormality either in the wall or in the adjacent structures



Position of the fingers during bimanual examination

Bimanual examination

- Palpation of the uterus
- Palpation of the uterine appendages
- Pouch of Douglas.



RECTAL OR RECTOABDOMINAL EXAMINATION

Rectal examination can be done in isolation or as an adjunct to vaginal examination.

Indications of Rectal Examination

Children or in adult virgins

Painful vaginal examination

Carcinoma cervix—to note the parametrial

involvement (base of the broad ligament and the uterosacral ligament can only be felt rectally) or involvement of the rectum

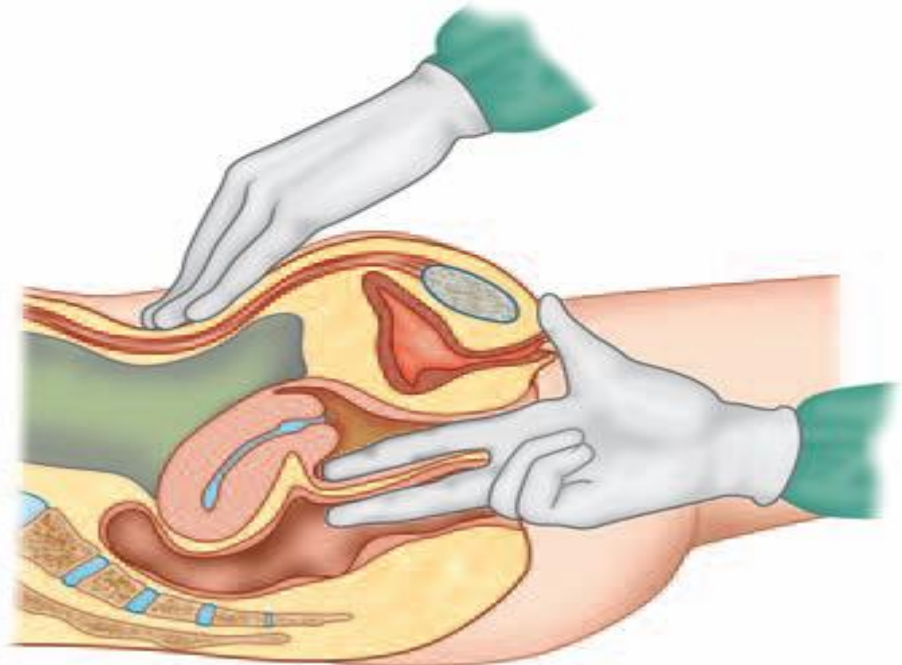
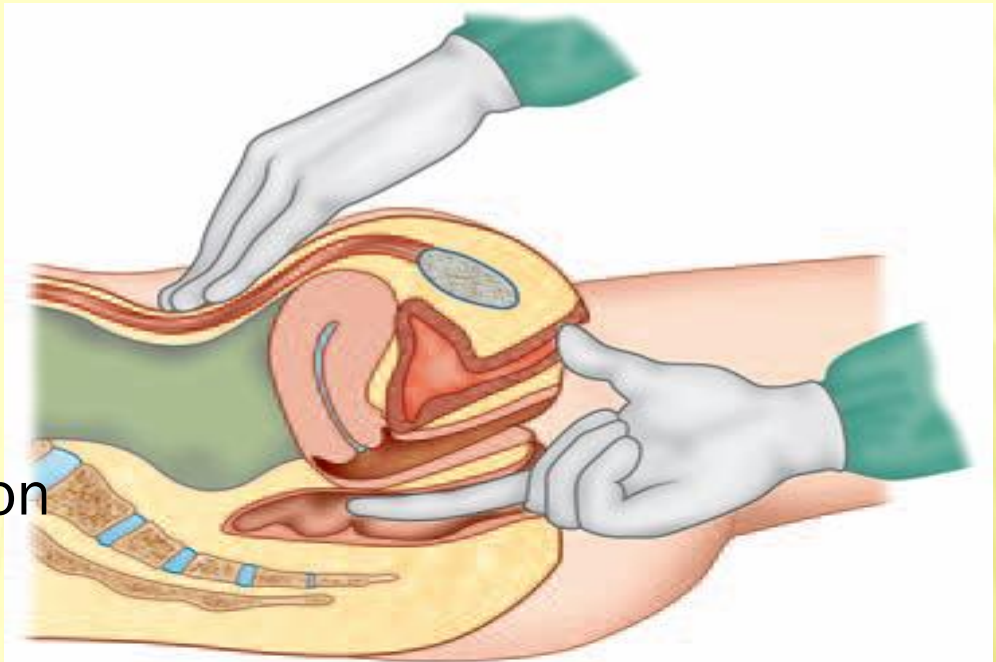
To corroborate the findings felt in the pouch of Douglas by bimanual vaginal examination

Atresia (agenesis) of vagina

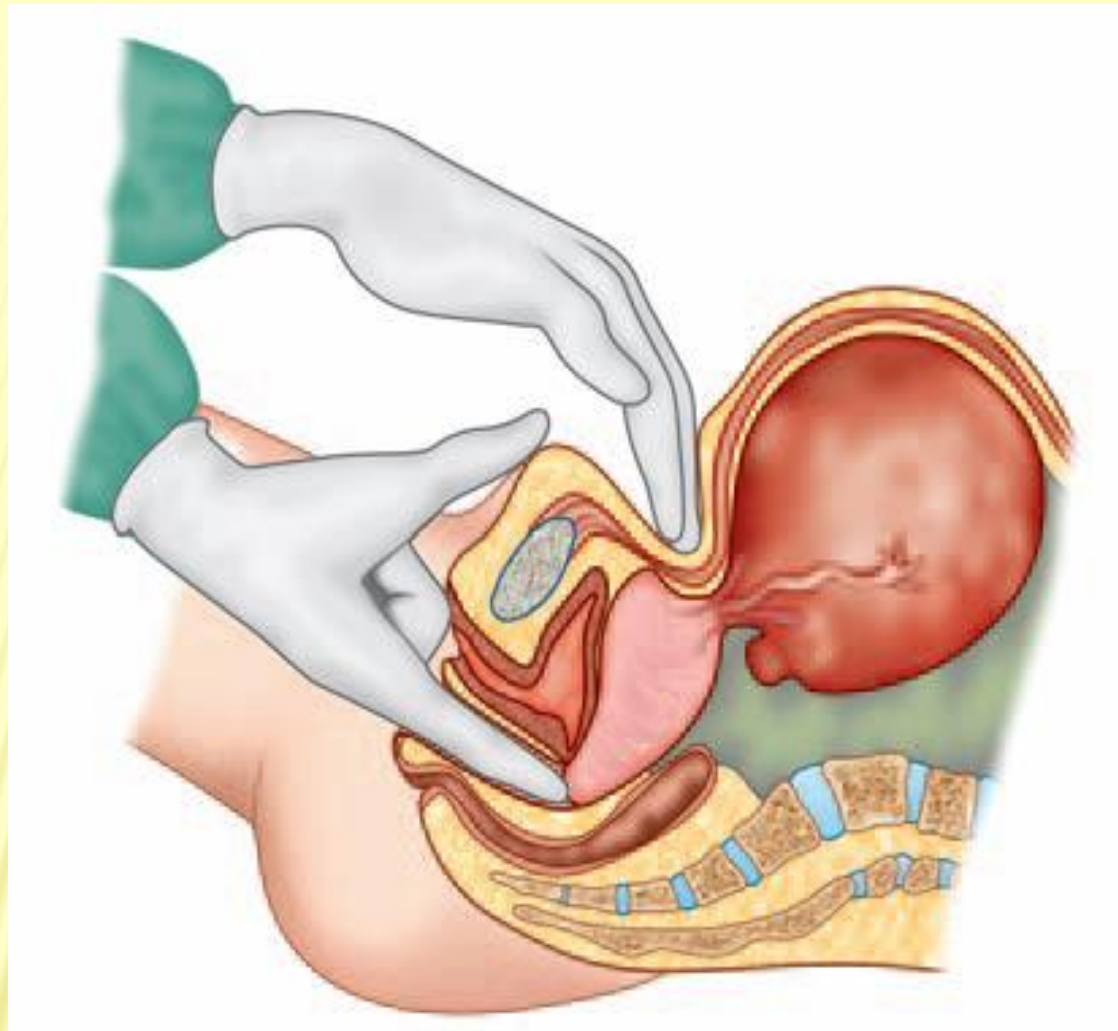
Patients having rectal symptoms

To diagnose rectocele and differentiate it from enterocele.

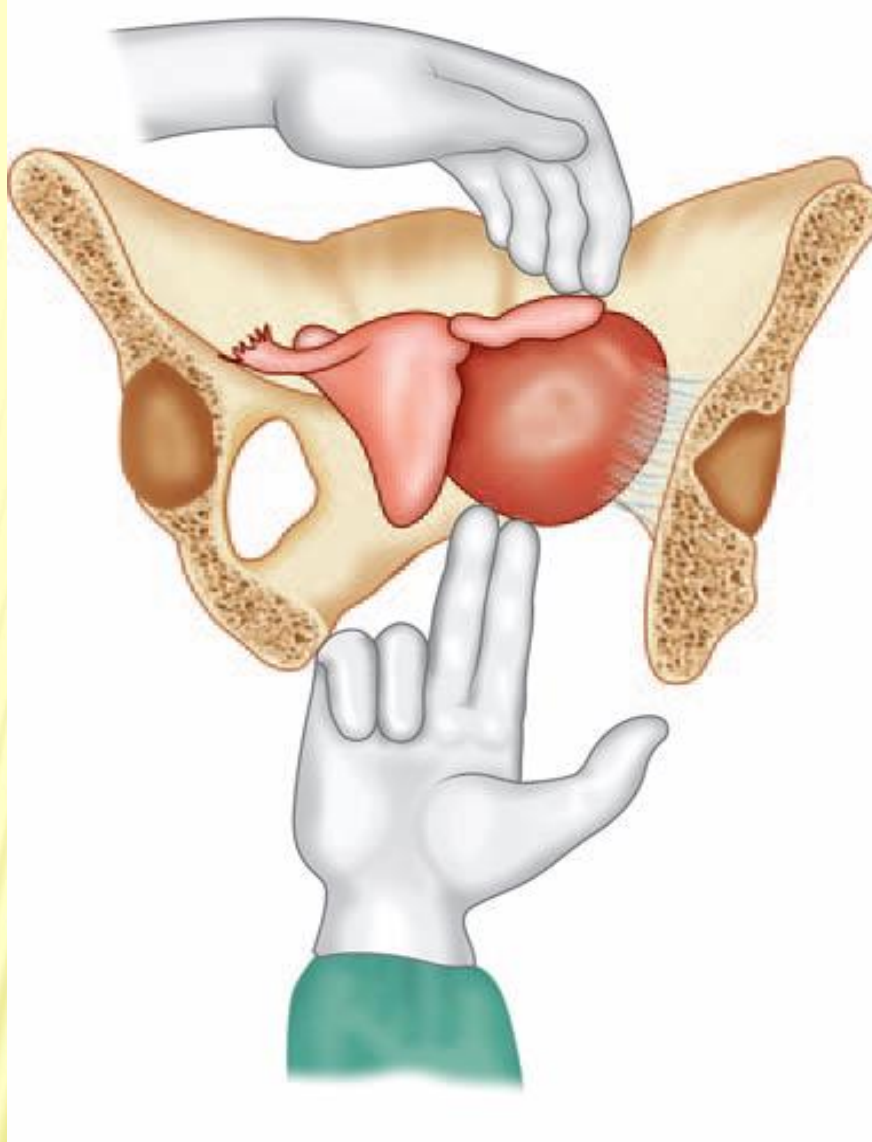
(A) Rectoabdominal;
(B) Rectovaginal examination



RECTOVAGINAL EXAMINATION: The procedure consists of introducing the index finger in the vagina and the middle finger in the rectum. This examination may help to determine whether the lesion is in the bowel or between the rectum and vagina. Any thickening or beading of uterosacral ligaments or presence of endometriotic nodules are noted. **This is of special help to differentiate a growth arising from the ovary or rectum**



Identification of ovarian tumor in
bimanual examination



Identification of an adnexal mass in bimanual examination